

# DESTABILIZATION OF THE COMMUNUTED CLAVICLE SHAFT FRACTURE DUE TO BREAKAGE OF THE TITANIUM LOCKING PLATE - MECHANICAL ANALYSIS

Zbigniew L. KOWALEWSKI<sup>1</sup>, Grzegorz SZCZĘSNY<sup>2</sup>, Tomasz LIBURA<sup>1</sup>, Adam BRODECKI<sup>1</sup>

<sup>1</sup>Department of Experimental Mechanics, IPPT, Polish Academy of Sciences, Warsaw, Poland,  
E-mail: [zkowalew@ippt.pan.pl](mailto:zkowalew@ippt.pan.pl); [tlibura@ippt.pan.pl](mailto:tlibura@ippt.pan.pl); [abrodec@ippt.pan.pl](mailto:abrodec@ippt.pan.pl)

<sup>2</sup>Department of Orthopedic Surgery and Traumatology, Medical University, Warsaw, Poland,  
E-mail: [grzegorz.szczesny@wum.edu.pl](mailto:grzegorz.szczesny@wum.edu.pl)

## 1. Introduction

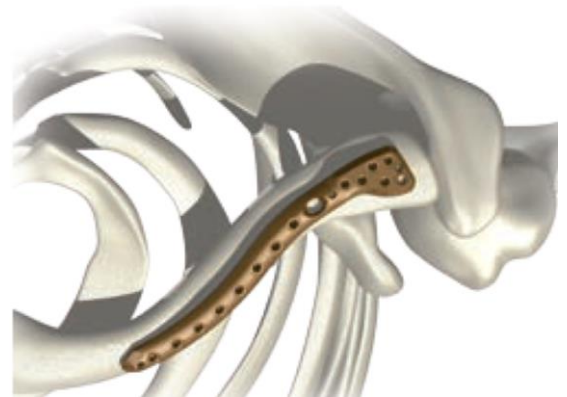
Implant break off destabilizing the fracture regularly complicates orthopedic procedures. It may be caused by implant's structural defect, its inappropriate usage, or massive overloads exceeding its strength [1, 2].

An analysis of the reason of implant breaking usually brings about troubles coming from limited insight into the incident, as patients often dissemble the genuine circumstances that led to the complication avoiding its responsibility. Especially, when they do not follow postoperative directions. Moreover, implant failure may also be used for clamor of compensation, bringing about several troubles to the manufacturer, to the hospital, and to the surgeon. Hence, recognizing the reason for implant breakings is valuable not only from medical, but also juridical and financial point of view.

The paper presents mechanical analysis of the patient, to whom the locking plate stabilizing comminuted fracture of the clavicle broke destabilizing it at the sixth postoperative week. Circumstances of the incidence were not clear, and therefore, mechanical analyses were made to formulate conclusions that could be helpful for other patients subjected to the similar situations.

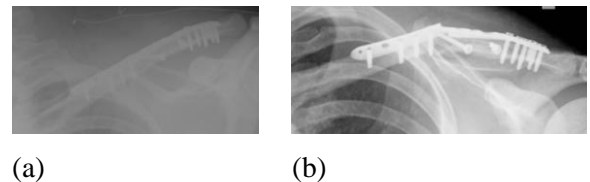
## 2. Problem presentation

33-years old men of 105 kg body weight and 188 cm height was operated on due to comminuted fracture of the shaft of the left clavicle. Fracture was anatomically reduced and stabilized with 2,8 mm Ti-6Al-4V, precontoured, angle stable, locking plate, Fig. 1 ("System 5.0", ChM, Poland) implanted on its superior surface.



**Fig.1.** General view of the locking plate [3].

Both intermediate bone fragments were additionally fixed with titanium cortical screws, Fig.2a. Postoperative wound healed uneventfully and patient was discharged with limb immobilized in shoulder brace for three weeks. After that, patient started rehabilitation, but was recommended to avoid massive physical loads.



**Fig. 2.** Postoperative x-ray (a), and the broken plate evidencing destabilized fracture (b).

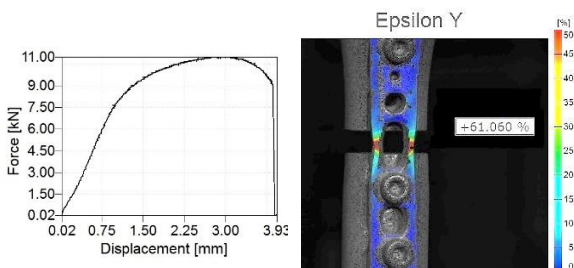
At the end of the sixth postoperative week patient reported sudden pain and noticeable click that occurred while closing the trunk lid of the car.

Performed x-ray revealed broken plate and destabilized fracture, Fig.2b. Patient was re-operated and plate was replaced [4].

### 3. Biomechanical analysis

For biomechanical analysis an analogous plate as the broken one coming from the same manufacturer was used. Ultimate tensile strength and yield point of its alloy (Ti-6Al-4V) were 960 and 850 MPa, respectively. Taking them into account with plate dimensions (length, thickness and width) together with length of clavicle's fragment (necessary for the leverage assessment) it is possible to estimate values of admissible loading under various stress states that cannot be exceeded, thus, protecting plate against the fracture due to overloading.

In order to approximate working conditions of the plate stabilizing broken bone the simple strength tests were carried out (uniaxial tension and simple bending). Assuming an uniaxial tensile conditions (i.e. driving force is acting along the length of the plate) the maximum force should be lower than 11,4 kN to avoid its fracture and lower than 10 kN to protect it against plastic flow processes leading to the permanent deformation of the plate, and thus, in consequence, changes its working conditions (additional components of loadings like bending or torsion may appear). In Fig. 3 the results of uniaxial tensile test supported by digital image correlation (DIC) technique were presented. They confirmed the typical standard parameters of tensile test for the material in question.




**Fig. 3.** Tensile characteristic of the plate material (Ti-6Al-4V) and strain distribution just before the fracture of plate.

In vast majority of cases, the clavicle moves in transverse plane forward and backward, bending the plate at its hole, and stretching its posterior branch, whereas the anterior one serves as a hinge. This is much worse working condition of the plate, because even relatively low forces (less than 50N) may lead to the stress value higher than the ultimate tensile strength of the plate.

To analyze an influence of the bending on the plate, the bending plane has to be determined, since for the same bending moment and the cross-section

of the plate the maximum stress depends on its orientation.



**Fig. 4.** Experimental setup for bending test of the plate.

For the plate considered here it may differ as much as four times. The lowest stress can be obtained, when the bending force is acting along the width of the plate, the largest if perpendicularly to its thickness. Five simple bending tests were carried out for selected lengths of bending arm: 50; 60; 70; 80 and 90 mm. For the most unfavorable case considered, i.e. simple bending with relatively small force (40 N), but acting over an arm of 90 mm (the distance from the site of the break to the clavico-acromial joint), the moment of the force reached 3,6 Nm, occurring to be sufficient to initiate the permanent deformation of the plate.

### 4. Conclusions

Superimposing the broken plate on patient's body one can conclude that its fracture had to be caused by a combination of loading that is typical for multiaxial stress, resulting from simultaneous action of tensile force, bending moment and torque. This indicates that patient had not respected postoperative recommendations to avoid any form of overloading.

### References

- [1] Bostman, O., Manninen, M., Pihlajamaki, H. Complications of plate fixation in fresh displaced mid clavicular fractures. *J Trauma*, 1997, 43, 778–783.
- [2] Shin, S.J., Do, N.H., Jang, K.Y. Risk factors for postoperative complications of displaced clavicular midshaft fractures. *J Trauma Acute Care Surg.*, 2012, 72(4), 1046-50.
- [3] *Manufacturer's material.*  
[https://chm.eu/uploads/C\\_5\\_clavicular\\_plates.pdf](https://chm.eu/uploads/C_5_clavicular_plates.pdf)
- [4] Szczęsny, G., Kowalewski, Z. Destabilization of the comminuted clavicle shaft fracture due to breakage of the titanium locking plate - biomechanical analysis. *Clin Surg.* 2018, 3, 2125.